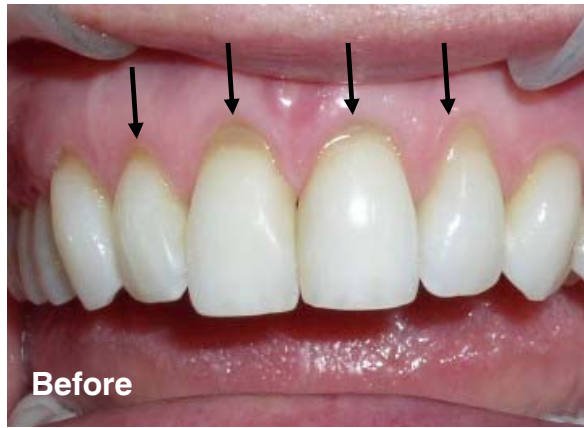

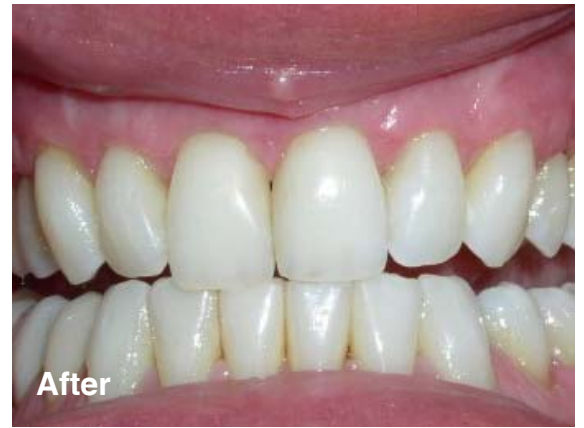Recession & Exposed Roots



Before

- 1) Coronally repositioned grafts #6-11

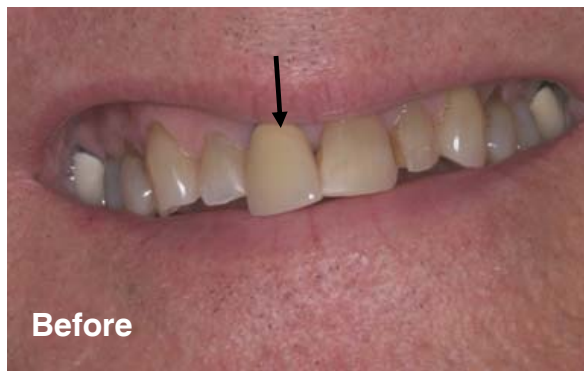Coronally Repositioned Grafts



After

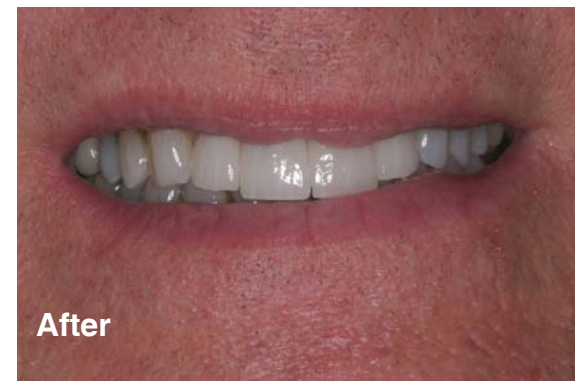Tooth Loss due to periodontal Disease & failing RCT

Fixed Bridge



Before

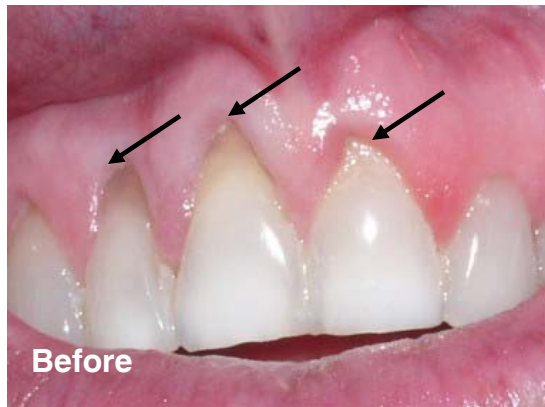- 1) Extracted #8
- 2) Bone graft & soft Tissue graft #8 for Ovate pontic development
- 3) Bleaching
- 4) Fixed Bridge #7-9, crown #10



After

Restorative By: C. Carter, D.D.S.

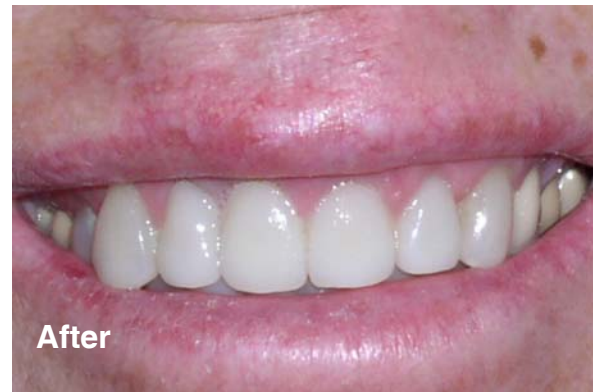Gingival Defects



Before

- 1) CTG #7,8,9
- 3) Porcelain crowns # 6-11

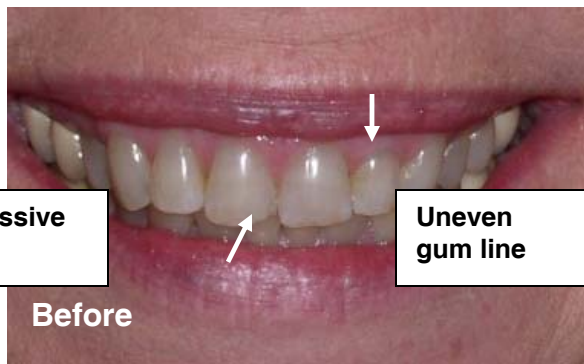
Connective Tissue Grafting & Porcelain Crowns



After

Restorative By: T. Mulcahy, D.D.S.

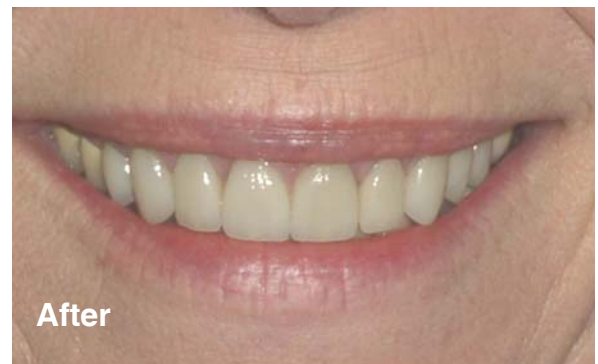Gingival Asymmetry



Before

- 1) Orthodontics
- 2) CTG #12 & Crown Lengthening #10-11
- 3) Veneers & Crowns #4-12

Connective Tissue Grafting, CL & Crowns



After

Restorative By: S. Daniel, D.D.S.